

# Functional Neuroanatomy of Spatial Working Memory in Children

Charles A. Nelson, Christopher S. Monk, Joseph Lin, Leslie J. Carver,  
Kathleen M. Thomas, and Charles L. Truwit  
University of Minnesota, Twin Cities Campus

Functional magnetic resonance imaging (fMRI) was used to examine spatial working memory in 8- to 11-year-old children tested under three conditions. In the visual condition, children were asked to examine the location of a dot on a screen. In the motor condition, children were instructed to push a button that corresponded to the location of a dot presented on a screen. In the memory condition, children were asked to remember the location of a dot presented 1 or 2 trials previously. Subtracting the activation of the motor condition from the memory condition revealed activity in the dorsal aspects of the prefrontal cortex and in the posterior parietal and anterior cingulate cortex. These findings were also obtained in the analysis of the memory minus visual conditions except that motor cortex activation was also observed. These findings parallel those reported in comparable studies of adults and suggest that fMRI may be a useful means of examining function–structure relations in developmental populations.

According to Baddeley (1986), working memory is the process of temporarily maintaining information in an active form so that it is available for further processing. Not surprisingly, this cognitive component may be involved in many common tasks such as planning, decision making, spatial navigation, and strategy use. In the context of development, it is likely that working memory may underlie the emergence of many abilities that are considered hallmarks of mature, higher level cognitive functions. In this article we explore the functional neuroanatomy of working memory in 8- to 11-year-old prepubescent children.

In the adult, the neural substrate for working memory varies depending on what is required of the person (see Goldman-Rakic, 1996). For example, dorsal aspects of the frontal cortex (including the superior and middle frontal gyri) may be disproportionately

involved in the processing of spatial working memory, whereas the ventral aspects (including the inferior prefrontal gyrus) may be more involved in working memory for objects and faces (Goldman-Rakic, 1996; Ungerleider, Courtney, & Haxby, 1998). Evidence for this comes from studies of both monkeys and humans. Single-cell recordings from nonhuman primates revealed that neurons in the dorsolateral prefrontal cortex responded preferentially during a spatial working memory task and were relatively inactive during pattern working memory (Wilson, Scalaidhe, & Goldman-Rakic, 1993). Moreover, when recordings were made from the inferior convexity of the prefrontal cortex, the reverse pattern was seen: Neurons fired preferentially during the pattern working memory task but were inactive during the spatial working memory task (Wilson et al., 1993). In a recent investigation using functional magnetic resonance imaging (fMRI), Courtney, Petit, Maisog, Ungerleider, and Haxby (1998) reported that the superior frontal sulcus of the human adult was bilaterally more active during a spatial working memory task than during a working memory task with faces. Unlike in monkeys, the activity in the superior frontal sulcus extended into the premotor region. Moreover, the same study found that the left inferior frontal cortex showed more sustained activity during face working memory than during spatial working memory. Thus, in adult nonhuman and human primates, the dorsal structures of the frontal cortex may be disproportionately involved in spatial working memory, and the ventral structures may be more involved in working memory for nonspatial information.

In addition to the functioning of the prefrontal cortex, the parietal region and anterior cingulate cortex also display activity during spatial working memory tasks. The posterior parietal region is part of the dorsal stream and, as such, is involved in the processing of spatial information (Ungerleider et al., 1998). Evidence for this comes from lesion and single-unit recording studies with monkeys, which have found that the posterior parietal region is both necessary and active during the processing of spatial information (Ungerleider & Haxby, 1994). Similarly, by means of positron emission tomography (PET), researchers found activation

---

Charles A. Nelson, Institute of Child Development and Department of Pediatrics, University of Minnesota, Twin Cities Campus; Christopher S. Monk, Leslie J. Carver, and Kathleen M. Thomas, Institute of Child Development, University of Minnesota, Twin Cities Campus; Joseph Lin and Charles L. Truwit, Department of Radiology, University of Minnesota, Twin Cities Campus.

Leslie J. Carver is now at the University of Washington. Kathleen M. Thomas is now at the Sackler Institute, Cornell University.

This research was supported by the John D. and Catherine T. MacArthur Foundation through its developmental functional magnetic resonance imaging consortium (members included B. J. Casey, Jonathan Cohen, Richie Davidson, Xiaoping Hu, Charles A. Nelson, Kathy O'Craven, Bruce Rosen, Robert Savoy, Charles Truwit, and Pat Turski); by National Institutes of Health Grant NS23389; and by National Institute of Child Health and Human Development Training Grant 5T32HD07151.

We are grateful to the children who agreed to participate in this study. We would also like to thank B. J. Casey and Jonathan Cohen for their help in launching this project and Xiaoping Hu, Kamil Ugurbil, and Tuong Le for setting up the experimental parameters.

Correspondence concerning this article should be addressed to Charles A. Nelson, Institute of Child Development, University of Minnesota, 51 East River Road, Minneapolis, Minnesota 55455. Electronic mail may be sent to canelson@tc.umn.edu.

of this region in humans during the processing of spatial information (Courtney, Ungerleider, Keil, & Haxby, 1996). Moreover, anatomical analysis of the monkey found reciprocal connections between the parietal lobe and dorsal aspects of the prefrontal cortex (e.g., Schwartz & Goldman-Rakic, 1984). Thus, not only do these studies suggest that the parietal region is involved in spatial memory, but Goldman-Rakic's (1996) work indicates that this area exchanges information with the dorsal prefrontal cortex.

As for the anterior cingulate cortex, this region is activated during tasks that involve working memory, language generation, and selective attention (Cabeza & Nyberg, 1997). Recently, in line with research showing activation of this region on seemingly disparate tasks, Carter et al. (1998) found that this region is activated when a task involves competition between various responses. Therefore, it is suggested that the anterior cingulate is sensitive to conditions under which errors are likely.

What about the development of working memory? First, by all accounts, developmental data from humans indicate that the neural structures that support working memory, particularly the prefrontal cortex, undergo protracted development (unfortunately, little is known about the development of the parietal cortex and cingulate). This is particularly true at the level of physiological and anatomical development. For example, Huttenlocher (1979, 1990, 1994; Huttenlocher & Dabholkar, 1997) has reported an exuberance of synapses in the middle frontal gyrus, with the number of synapses in infancy far exceeding adult numbers. This peak of overproduction occurs at 1 year of age, followed by a gradual decline in numbers of synapses until adult levels are obtained sometime during mid- to late adolescence. Second, investigations with PET indicate that mature levels of metabolic activity are slow to emerge in the frontal cortex relative to other areas. Indeed, metabolic activity in the frontal cortex lags behind all other cortical regions and only approaches adult values by 1 year of age, with continued development over the next decade or more (Chugani, 1994; Chugani & Phelps, 1986). Third, an examination of the histochemical development of the human frontal cortex reveals that acetylcholinesterase reactivity in Cortical Layer III (pyramidal field) is not fully developed until young adulthood (Kostovic, Skavic, & Strinovic, 1988; Mesulam & Geula, 1988).<sup>1</sup> Fourth, myelination of the prefrontal cortex is protracted and does not reach adult levels until adolescence (Jernigan, Trauner, Hesselink, & Tallal, 1991; Yakovlev & LeCours, 1967). Fifth, using measures of electroencephalogram (EEG) coherence, Thatcher (1992) proposed that (a) the cortex as a whole undergoes a series of cycles in development (in which short- and long-range intra- and intercortical connections are laid down), (b) this process is orchestrated by the frontal cortex, and (c) this process continues beyond the preschool period. Collectively, these findings suggest that the prefrontal cortex—a region known to be involved in working memory—is slow to develop and may not reach maturity until adolescence.

Support for the protracted physiologic and anatomic development of the prefrontal cortex can also be found in the behavioral literature. There is evidence that some working memory capacity emerges during infancy. For example, Diamond and colleagues (e.g., Diamond, 1985; Diamond & Doar, 1989; Diamond & Goldman-Rakic, 1989) have proposed that the ability to tolerate increasingly long delays on the Piagetian A-not-B task and the delayed response task is made possible by the development of a specific region within the prefrontal cortex, the dorsolateral region

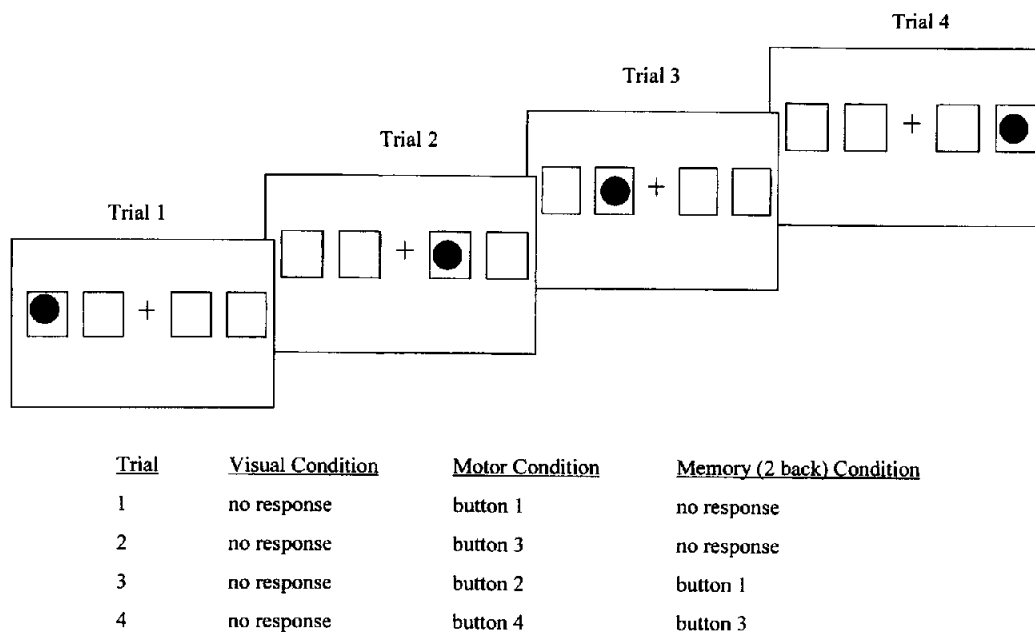
(although some authors have questioned this hypothesis; see Johnson, 1998; Nelson, 1995). Gilmore and Johnson (1995) have reported that 6-month-old infants can hold in working memory the spatial location of a cued target for as long as 4 s, which again suggests that some working memory capacity emerges during the infancy period.

These impressive feats notwithstanding, the bulk of the child neuropsychological literature clearly supports the view of a more protracted course of prefrontal development, consistent with the literature on synaptogenesis. For example, using a variety of prefrontal tasks that require working memory, Luciana and Nelson (1998) observed a marked improvement from 4 years through early adolescence; indeed, these authors observed that on a spatial working memory task and on more difficult Tower of London problems (i.e., those requiring four and five moves), the improvement from 8 years to adolescence/adulthood was at least as great as the improvement from 4 to 8 years. Similarly, 10- and 11-year-old children do not perform as well as adults on a test of visual working memory for patterns (Miles, Morgan, Milne, & Moris, 1996). In addition, in a study in which children between the ages of 7 and 15 were tested for spatial and verbal memory span, significant improvements in performance continued up through the oldest age group (Isaacs & Vargha-Khadem, 1989). Finally, Fernández et al. (1998) demonstrated that reduced EEG power at the frontal leads preceded incorrect responses during a test of verbal working memory in 8- to 10-year-old children, again pointing to the link between working memory and the prefrontal cortex. On the whole, these studies indicate that mature functioning in working memory tasks emerges during middle childhood, with considerable room for improvement through adolescence.

In the current study we sought to examine the functional anatomic organization of working memory during middle childhood. We selected this age for two reasons. First, it is difficult to use fMRI in children younger than 5 to 6 years of age (primarily because of their inability to sit still for a long time). Second, we wished to evaluate an age period when expected levels of performance might begin to resemble those of the adult. In this context we hypothesized that 8- to 11-year-old children would show distributions of functional brain activity that would bear some similarity to that of adults. It is important to note that Casey et al. (1995) used a nonspatial working memory task in which research participants were presented with a sequence of letters and, when the letter in a given trial matched the letter the participant saw two trials before, the person was to press a button. These authors reported that in a test of nonspatial working memory, 9- to 11-year-old children showed activation in the anterior cingulate and inferior and middle frontal gyri that was similar to what Cohen et al. (1994) observed in adults tested in the same paradigm. Thus, like adults, children show more activation in the ventral prefrontal cortex relative to the dorsal prefrontal cortex for nonspatial working memory tasks. This indicates that distinct functions of the prefrontal regions are already evident in children before the onset of puberty. Therefore, perhaps the delayed improvements in working memory are reflected in subtle neuroanatomical changes rather

<sup>1</sup> Acetylcholinesterase is an enzyme involved in the termination of acetylcholine synaptic activity, and thus this reactivity is thought to be a marker of the chemical maturity of this region.

# Behavioral Paradigm



*Figure 1.* The behavioral paradigm. A colored dot was presented randomly in squares across trials. In the visual task, participants watched the dot. In the motor task, participants pressed the button that corresponded to the location of the dot; in the memory task, they pressed a button corresponding to where the dot was previously.

than in the inclusion of additional structures into the working memory circuitry.

In the present study, we used a spatial working memory task that has previously been used with adults (Casey et al., 1998). Casey et al. (1998) reported that in addition to activity in the anterior cingulate and posterior parietal cortex, there was activation in both the middle and superior frontal gyri. Moreover, in line with Courtney et al. (1998), the activity in the superior frontal gyri spanned both the prefrontal cortex and the premotor cortex. Consequently, although both adults and children in the nonspatial working memory study exhibited more activity in the ventral regions, the adults in the spatial working memory task showed higher levels of activity in the dorsal regions of the frontal cortex. In the present study, we sought to examine the pattern of activity children would show when they performed the same spatial working memory task used by Casey et al. (1998). This would permit an evaluation of the functioning of the prefrontal cortex in a prepubescent population. Furthermore, although Casey et al. (1995) imaged the frontal lobe, we acquired data on the whole brain as children performed the spatial working memory task. Consequently, the developmental status of the entire neural circuitry that supports working memory could be assessed.

Following Casey et al. (1995), we expected the children in our spatial working memory task to demonstrate a pattern of activation similar to that seen in adult spatial working memory studies. In particular, we predicted activation of dorsal structures rather than ventral structures of the prefrontal cortex and, in line with Courtney et al. (1998) and Casey et al. (1998), we expected that this activation would extend into the premotor cortex. We also pre-

dicted the involvement of two additional areas: the posterior parietal cortex because of its role in processing spatial information and the anterior cingulate because of its role in monitoring attentional resources.

## Method

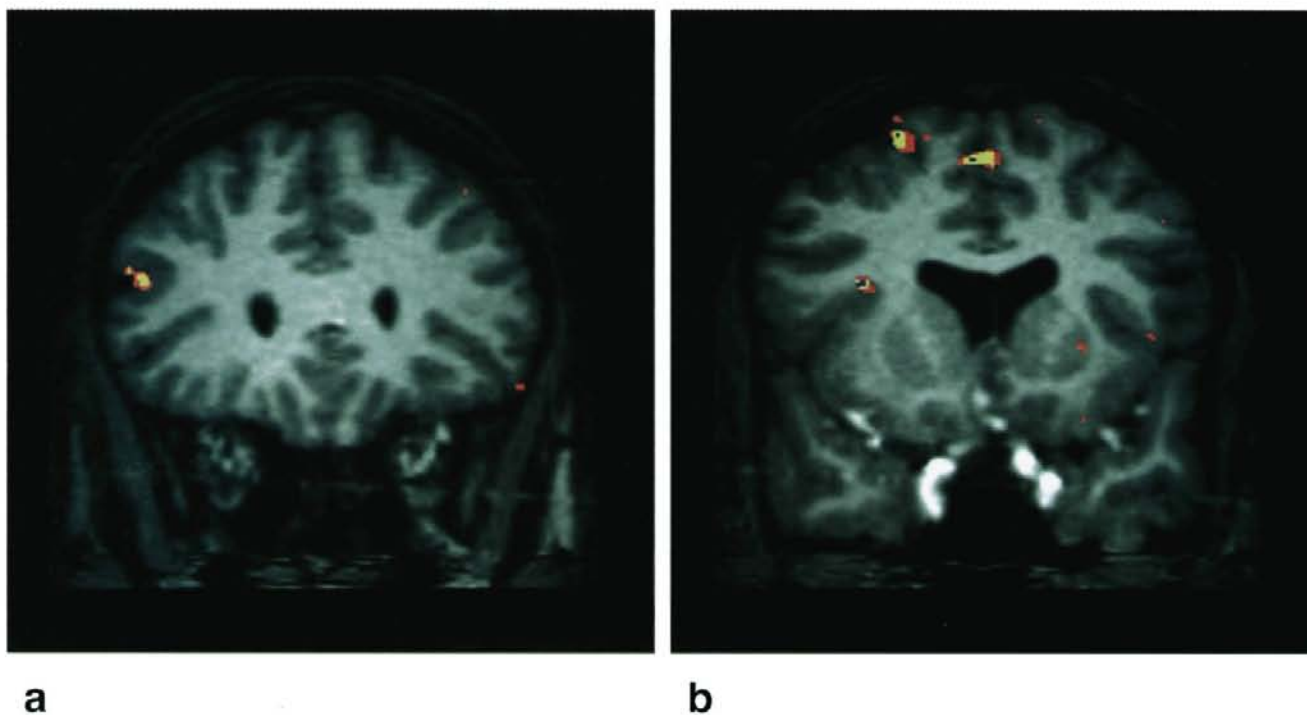
The Institutional Review Board of the University of Minnesota approved all testing. Children gave informed assent, and their parents gave consent, again in compliance with the review board's requirements.

### Participants

Normally developing, right-handed children aged 8 to 11 years 7 months with no known neurological complications served as participants. All were Caucasian, from middle to upper middle class well-educated families, and paid \$15 for their participation. We tested a total of 14 participants, 9 of whom yielded data with minimum artifact (see below for a description of permissible data).

### Procedure

After acclimating to the magnetic resonance (MR) environment and having practiced the task (see below), participants were asked to lie on their backs in the scanner. Their heads were placed in a head coil, and a mirror was placed directly above their eyes. At the foot of the bed was a large (54.6 × 76.2 cm) screen onto which images would be rear-projected by means of an In Focus Lite Pro Model 580 LCD Projector (In Focus Company, Wilsonville, OR). By looking straight up into the mirror, participants could easily see these images on the screen (from a distance of approximately 3.7 m). Participants were given a button box (containing



**Figure 2.** A summary activation map across all participants in the memory versus motor comparison: (a) Activity in the middle frontal gyrus. (b) Activity in the superior frontal gyrus. The colors indicate areas in which participants showed activation: blue = 7 participants; yellow = 6 participants; red = 5 participants.

nonmagnetic material) that was placed in their right (dominant) hand, and each finger was placed on one of four buttons. Each button (from left to right) corresponded to one of four locations on the screen.

### Stimuli and Task

There were four boxes (each box was  $6.6 \times 6.6$  cm; approximately  $1^\circ \times 1^\circ$ ) arranged in a horizontal line that appeared on the screen (see Figure 1 for details). Participants were tested under three conditions: A *visual* task, in which they needed to visually monitor the location of the dot; a *motor* task, in which they simply had to press the button that corresponded to the location of a dot (e.g., press Button 1 when an object appeared in Location 1, etc.); and a *memory* task (N-back), in which the children were told to push the button that corresponded to where the dot was previously. The three tasks were presented in a fixed order (visual, motor, memory, memory, visual, motor, memory, motor, visual) across participants. Some children responded to where the dot was two trials earlier, whereas others responded to where the stimulus was on the previous trial.<sup>2</sup> Across the three conditions (visual, motor, and memory), stimuli were presented for 500 ms, with an interstimulus interval of 1,500 ms. For each of the three conditions, three blocks of 19 trials were presented, for a total of 171 trials. All conditions were conducted within the same scanning run.

### MRI Recording and Data Reduction

All studies were conducted on a Siemens Magnetom 1.5T Vision system (Siemens Company, Munich, Germany), with a volume head coil. Conventional MR imaging was performed to acquire two-dimensional (2-D) anatomical images. Sixteen oblique sagittal slices (6 mm thick, with a gap of 0.6 mm) were obtained with spin echo acquisitions as follows: TR (repetition time), 580 ms; TE (echo time), 14 ms; a flip angle of  $90^\circ$ ; field of view,  $220 \times 220 \times 105$  mm; matrix,  $256 \times 256$ .

In addition, an MPRAGE (Magnetization Prepared Rapid Gradient Echo) imaging sequence was applied to acquire 3-D anatomical images for

each participant. The physical sequence was applied to acquire 3-D sequences as follows: TR, 15 ms; TE, 7 ms; a flip angle of  $8^\circ$ ; field of view,  $220 \times 220 \times 105$  mm; matrix,  $256 \times 256$ ; 1 slab thickness of 162 mm with 100 partitions; sagittal orientation.

Functional images of the same slice thickness and in the same slice location as the 2-D anatomical images were obtained with a T2-weighted echo planar imaging sequence. The physical parameters were as follows: TR, 3,000 ms; TE, 66 ms; a flip angle of  $90^\circ$ ; field of view,  $220 \times 220 \times 105$  mm; matrix,  $128 \times 128$ . The raw data were preprocessed using a physiological artifact reduction method (Le & Hu, 1996) to remove ghosting. For participants with less than 2 mm of movement, images were then motion corrected with the statistical parametric mapping method. Children with movement that was greater than 2 mm were excluded from further analysis. Furthermore, an image-processing software package, STIMULATE (Strupp, 1997), was applied to analyze the functional maps from the difference of brain signal intensities between the task and control periods by using a Student's *t* test with significance set to  $p < .001$ . The images of the activated pixels were then overlaid on the corresponding anatomic images for each participant, and a summary activation map at a Talairach coordinate box (Talairach & Tournoux, 1988) across participants was generated by means of the image-processing program.

<sup>2</sup> Although it would have been desirable to have had all participants perform the task at the same level of difficulty, pilot data indicated that some children found the N-1 task too easy and others found the N-2 task too difficult. Thus, we decided to permit participants to perform the task at the level of competence observed during training. In either case (N-1 or N-2), the task demands were the same: Children were required to encode the location of one stimulus while pressing a button to the location of a previous stimulus.

## Results

### Functional Neuroanatomical Data

Functional maps constructed from the difference ( $p < .01$ ) of MR signals between memory and motor conditions revealed activation in the middle frontal gyrus. Specifically, 8 of 9 participants showed activation in Brodmann's Area 46 of the right middle frontal gyrus, and 7 participants presented activation in Brodmann's Area 10 of the right middle frontal gyrus. Furthermore, 7 participants showed activation in three separate regions of the superior frontal gyrus: right Brodmann's Area 9; right/middle Brodmann's Area 6; and bilateral/middle Brodmann's Area 6. A summary activation map for the middle and superior frontal gyri is presented in Figure 2.

Activation was also revealed in Brodmann's Area 32 and 24 of the left cingulate in 7 of the 9 participants. In terms of the parietal lobe, 7 participants displayed activity in the inferior parietal lobe (Brodmann's Area 40) as well in the superior parietal lobe (Brodmann's Area 7). In addition, Brodmann's Area 19 of the middle occipital gyrus exhibited activation. A summary of the activated areas in the memory minus motor analysis is presented in Table 1. Finally, the analysis of the memory minus the visual conditions revealed analogous activation to that described previously except that the motor cortex (Brodmann's Area 4) was also activated.

### Behavioral Performance

We examined the button-press accuracy in the memory task for all 9 participants. The range of accuracy varied between 88.9% and 47.0% ( $M = 68\%$ ). A one-sample  $t$  test indicated that participants performed significantly better than chance (25%),  $t(8) = 10.81$ ,  $p < .001$ . Because all participants performed at levels above chance, it appears that they understood the task.

No consistent pattern appears obvious in a comparison of button-press accuracy and functional activation. Thus, for example, Participant 3, whose accuracy was only 66%, showed

prefrontal and cingulate activation, whereas Participant 4, with the highest level of accuracy, showed activation in the same areas (our sample size was too small to statistically compare behavioral function with activation). It may be that the activation is related to understanding the task and the effort to complete it rather than to the level of accuracy at which the task is completed.

## Discussion

The results of this study demonstrate that prepubescent children show a pattern of brain activation in a spatial working memory task that is remarkably similar to that of adults (i.e., dorsal aspects of the frontal cortex, posterior parietal area, and anterior cingulate cortex). In particular, following the framework of the dorsal and ventral streams, these findings show activation not only in the posterior parietal region but also in the dorsal aspects of the frontal cortex (middle and superior frontal gyri), with less activation seen in the ventral areas. By contrast, in the nonspatial working memory task with children reported by Casey et al. (1995), more ventral aspects of the prefrontal cortex were activated. Taken together, these studies suggest that the division of labor of the dorsal and ventral streams (Goldman-Rakic, 1996; Ungerleider et al., 1998) is already evident in the prefrontal cortex before puberty.

A somewhat unexpected finding from this study was that right was greater than left hemisphere activation in the prefrontal and parietal cortices. This finding is consistent with several previous reports of spatial working memory in adults. McCarthy et al. (1994) found activation in the right prefrontal cortex in a spatial working memory task. Owen, Evans, and Petrides (1996) found right hemisphere activation in the mid-dorsolateral prefrontal cortex during tasks that required spatial information to be held in working memory and manipulated. Our results are inconsistent, however, with the findings of Casey et al. (1998), who failed to

Table 1  
Areas of Activation Across Participants

Region and hemisphere	Brodmann's area	Talairach coordinates			<i>n</i>
		<i>X</i>	<i>Y</i>	<i>Z</i>	
Middle frontal gyrus					
Right	46	-4.85	2.23	-0.58	8
Right	10	-1.78	3.73	-1.18	7
Superior frontal gyrus					
Right	9	-2.96	0.80	-2.08	7
Right middle	6	-2.60	-0.40	-5.83	7
Right/left/middle	6	2.26	-1.38	-6.20	7
Cingulate					
Left	32	4.23	0.35	-3.43	7
Left	24	2.73	1.25	-0.95	7
Inferior parietal lobule					
Right	40	-3.58	-3.28	-2.60	7
Superior parietal lobule					
Right	7	-1.48	-7.23	-4.70	7
Middle occipital gyrus V4/V5					
Right	19	-2.75	-7.90	-3.28	7

observe laterality differences in task performance using the same task we did.<sup>3</sup>

Kelley et al. (1998) tested participants on word and line drawings of objects and faces. Left dorsal frontal activation was observed for the encoding of words, and right dorsal frontal activation was observed for the encoding of faces. However, for drawings of nameable objects, bilateral activation was found. Thus, during memory encoding, prefrontal cortex activation is lateralized depending on the nature of the task. Similarly, Smith, Jonides, and Koeppe (1996), using PET, showed a dissociation between activation for spatial and verbal working memory. When participants were instructed to hold the identity of letters (verbal working memory) on line, left hemisphere parietal cortex activation was observed. However, when they were instructed to retain the location of several objects, right prefrontal activation was observed. In a task in which participants had to use spatial working memory for verbal material (the location of letters), both left and right prefrontal as well as left parietal activation was observed. Thus, the results of Smith et al. (1996) suggest that even in spatial working memory tasks, verbalization can modify the systems that are used. Perhaps the adults in the Casey et al. (1998) study recorded the information verbally (e.g., "remember that the stimulus was to the far right, then to the far left"). Anecdotally, adult participants we saw for pilot testing indicated that they used these verbal strategies. Unfortunately, we do not have information about whether the adults tested by Casey et al. (1998) used verbal strategies, nor do we have information about any strategy used by the children in the present experiment. However, Ornstein, Naus, and Liberty (1975) demonstrated that the effective use of verbal strategies in a short-term memory task follows a slow developmental trajectory. In particular, verbal rehearsal of to-be-remembered information is elaborated more fully and effectively by adolescents than by younger children. Therefore, it is likely that the children in the present study did not use verbal rehearsal to the same extent as the adults did in Casey et al. (1998), or perhaps the children chose not to use a verbal strategy at all.

Activation in parietal areas may also be related to accuracy and effort expended in the task. In nonhuman primates, activation of the inferior parietal cortex and prefrontal cortex was related to the memory demands of a spatial memory task and the sensory motor demands, respectively (Friedman & Goldman-Rakic, 1994). Further, in inferior parietal subareas, activation was related to accuracy of performance. In the present study, behavioral performance was not apparently related to activation in either area. However, it remains possible that with larger sample sizes and more variability in performance (e.g., by including some children for whom the task is very easy and others for whom it is very difficult), such relations will emerge. Future research efforts with children and adults should include monitoring of strategy use and its effects, as well as information about the relation between performance, task demands, and sensorimotor demands of the tasks.

As in most fMRI studies, this study makes the assumption of pure insertion (for a review, see Friston et al., 1996). That is, when activation from the motor condition is subtracted from activation in the working memory condition, we assume that the residual activity is due to working memory. However, it is possible that the working memory task also recruits other cognitive operations to a greater degree than the motor task. For instance, attention or vigilance may be modulated across these two tasks. Indeed, the

cingulate, a structure known to be modulated by task demands (Barch et al., 1997) and response completion (Carter et al., 1998), showed increased activation in the working memory task in both children and adults. Furthermore, as in the adult analogue of this study, V4 and V5 of the visual cortex (Brodmann's Area 19) were also more active in the working memory task, and this region is known to display increased activity for visual tasks that require attention (Beauchamp, Cox, & DeYoe, 1997). Consequently, the increased task demands of the working memory condition may influence which neural structures are recruited, and thus it may be argued that the regions activated in this task may not all be purely involved in the cognitive operation of working memory.

However, in an adult fMRI study, the dorsolateral prefrontal and parietal cortices were specifically activated by working memory and not by increased task demands (Barch et al., 1997). Barch and colleagues administered an N-back working memory task and found that increased delay led to increased activation in the prefrontal cortex (Brodmann's Area 9 and 46) and in the parietal cortex (Brodmann's Area 40 and 7), but no changes were found in other areas, such as the cingulate. (It is important to note that in Barch's study, increasing the delay was not considered to lead to increases in the task demands, because this manipulation does not lead to decreased performance.) In contrast, when the task demands were increased by degrading the visual stimuli, activity in the dorsolateral prefrontal and parietal cortices did not change, but increased activity was found in the anterior cingulate. Thus, activity in the dorsolateral prefrontal and parietal cortices appears to be specifically involved in the cognitive operations of working memory and not simply activated in response to increased task demands. Moreover, in a separate study, activation in the dorsolateral prefrontal and parietal cortices increased with increased memory load in an N-back working memory task (Cohen et al., 1997), providing further evidence that these regions are specifically involved in working memory. The findings described above suggest that the activity we found in the dorsolateral prefrontal cortex and in the parietal area may be specifically involved in working memory, but the activation of the cingulate and the extrastriate cortex may be due to the increased task demands of the working memory condition.

In summary, there are two major findings from this study. First, our results parallel those obtained from studies of spatial working memory in adults (e.g., Casey et al., 1998; McCarthy et al., 1994) and extend those from a comparable study done with children (Casey et al., 1995). Accordingly, it would appear that the neural substrate thought to underlie spatial working memory may be adultlike prior to the onset of puberty, *at least given the demands of our task*. In the future it may be wise to use an event-related fMRI paradigm, in which the task demands can be varied within a given session for a given child. In so doing we may be able to better couple the relation between behavior and brain activation

<sup>3</sup> In the Casey et al. (1998) study, fMRI data were collected at four different institutions (University of Pittsburgh, University of Wisconsin—Madison, University of Minnesota, Harvard University) by means of the same experimental protocol, although only three of these sites reported the corresponding behavioral findings. Using an N-back of 2, percent accuracy across these sites ranged from 86% to 95%, all considerably higher than that of the children in the current study.



and at the same time examine individual differences in functional neuroanatomy. Additionally, by using higher field magnets (in our case, 4 or 7 Tesla) in testing children, we may be able to distinguish subtle differences between 8- to 11-year-old children and adults. Regardless of future directions, our results do suggest that fMRI is feasible in children. As such, we would encourage further exploration of this methodology as a means of exploring other domains of cognitive development and as a noninvasive tool with which to study brain development.

## References

- Baddeley, A. D. (1986). *Working memory*. Oxford, England: Oxford University Press.
- Barch, D. M., Braver, T. S., Nystrom, L. E., Forman, S. D., Noll, D. C., & Cohen, J. D. (1997). Dissociating working memory from task difficulty in human prefrontal cortex. *Neuropsychologia*, *35*, 1373–1380.
- Beauchamp, M. S., Cox, R. W., & DeYoe, E. A. (1997). Graded effects of spatial and featural attention on human area MT and associated motion processing areas. *Journal of Neurophysiology*, *78*, 516–520.
- Cabeza, R., & Nyberg, L. (1997). Imaging cognition: An empirical review of PET studies with normal subjects. *Journal of Cognitive Neuroscience*, *9*, 1–26.
- Carter, C. S., Braver, T. S., Barch, D. M., Botvinick, M. M., Noll, D., & Cohen, J. D. (1998, May). Anterior cingulate cortex, error detection, and the online monitoring of performance. *Science*, *280*, 747–749.
- Casey, B. J., Cohen, J. D., Craven, K., Davidson, R. J., Irwin, W., Nelson, C. A., Noll, D. C., Hu, X., Lowe, M., Rosen, B., Truwit, C., & Turski, P. A. (1998). Reproducibility of fMRI results across four institutions. *Neuroimage*, *8*, 249–261.
- Casey, B. J., Cohen, J. D., Jezzard, P., Turner, R., Noll, D. C., Trainor, R. J., Giedd, J., Kaysen, D., Hertz-Pannier, L., & Rapoport, J. L. (1995). Activation of prefrontal cortex in children during a non-spatial working memory task with functional MRI. *Neuroimage*, *2*, 221–229.
- Chugani, H. T. (1994). Development of regional brain glucose metabolism in relation to behavior and plasticity. In G. Dawson & K. Fischer (Eds.), *Human behavior and the developing brain* (pp. 153–175). New York: Guilford Press.
- Chugani, H. T., & Phelps, M. E. (1986, February 21). Maturational changes in cerebral function in infants determined by 18FDG positron emission tomography. *Science*, *231*, 840–843.
- Cohen, J. D., Forman, S. D., Braver, T. S., Casey, B. J., Servan-Schreiber, D., & Noll, D. C. (1994). Activation of the prefrontal cortex in a nonspatial working memory task with functional MRI. *Human Brain Mapping*, *1*, 293–304.
- Cohen, J. D., Perlstein, W. M., Braver, T. S., Nystrom, L. E., Noll, D. C., Jonides, J., & Smith, E. E. (1997, April 10). Temporal dynamics of brain activation during a working memory task. *Nature*, *386*, 604–608.
- Courtney, S. M., Petit, L., Maisog, J. M., Ungerleider, L. G., & Haxby, J. V. (1998, February 27). An area specialized for spatial working memory in human frontal cortex. *Science*, *279*, 1347–1351.
- Courtney, S. M., Ungerleider, L. G., Keil, K., & Haxby, J. V. (1996). Object and spatial visual working memory activation separate neural systems in human cortex. *Cerebral Cortex*, *6*, 39–49.
- Diamond, A. (1985). Development of the ability to use recall to guide action, as indicated by infants' performance on AB. *Child Development*, *56*, 868–883.
- Diamond, A., & Doar, B. (1989). The performance of human infants on a measure of frontal cortex function, the delayed response task. *Developmental Psychobiology*, *22*, 271–294.
- Diamond, A., & Goldman-Rakic, P. S. (1989). Comparison of human infants and rhesus monkeys on Piaget's AB task: Evidence for dependence on dorsolateral prefrontal cortex. *Experimental Brain Research*, *74*, 24–40.
- Fernández, T., Harmony, T., Silva, J., Galan, L., Diaz-Comas, L., Bosch, J., Rodriguez, M., Fernandez-Bouzas, A., Yanez, G., Otero, G., & Marosi, E. (1998). Relationship of specific EEG frequencies at specific brain areas with performance. *Neuroreport*, *9*, 3681–3687.
- Friedman, H. R., & Goldman-Rakic, P. S. (1994). Coactivation of prefrontal cortex and inferior parietal cortex in working memory tasks revealed by 2DG functional mapping in the rhesus monkey. *Journal of Neuroscience*, *14*, 2775–2788.
- Friston, K. J., Price, C. J., Fletcher, P., Moore, C., Frackowiak, R. S. J., & Dolan, R. J. (1996). The trouble with cognitive subtraction. *Neuroimage*, *4*, 97–104.
- Gilmore, R. O., & Johnson, M. H. (1995). Working memory in infancy: Six-month-olds' performance on two versions of the oculomotor delayed response task. *Journal of Experimental Child Psychology*, *59*, 397–418.
- Goldman-Rakic, P. S. (1996). Regional and cellular fractionation of working memory. *Proceedings of the National Academy of Sciences, USA*, *93*, 13473–13480.
- Huttenlocher, P. R. (1979). Synaptic density in human frontal cortex: Developmental changes and effects of aging. *Brain Research*, *163*, 195–205.
- Huttenlocher, P. R. (1990). Morphometric study of human cerebral cortex development. *Neuropsychologia*, *28*, 517–527.
- Huttenlocher, P. R. (1994). Synaptogenesis, synapse elimination, and neural plasticity in human cerebral cortex. In C. A. Nelson (Ed.), *Minnesota Symposium on Child Psychology: Vol. 27. Threats to optimal development: Integrating biological, psychological, and social risk factors* (pp. 35–54). Hillsdale, NJ: Erlbaum.
- Huttenlocher, P. R., & Dabholkar, A. S. (1997). Regional differences in synaptogenesis in human cerebral cortex. *Journal of Comparative Neurology*, *387*, 167–178.
- Isaacs, E. B., & Vargha-Khadem, F. (1989). Differential course of development of spatial and verbal memory span: A normative study. *British Journal of Developmental Psychology*, *1989*, 377–380.
- Jernigan, T. L., Trauner, D. A., Hesselink, J. R., & Tallal, P. A. (1991). Maturation of human cerebrum observed in vivo during adolescence. *Brain*, *114*, 2037–2049.
- Johnson, M. H. (1998). The neural basis of cognitive development. In W. Damon (Ed.), *Handbook of child psychology* (5th ed., pp. 1–49). New York: Wiley.
- Kelley, W. M., Miezin, F. M., McDermott, K. B., Buckner, R. L., Raichle, M. E., Cohen, N. J., Ollinger, J. M., Akbudak, E., Conturo, T. E., Snyder, A. Z., & Petersen, S. E. (1998). Hemispheric specialization in human dorsal frontal cortex and medial temporal lobe for verbal and nonverbal memory encoding. *Neuron*, *20*, 927–936.
- Kostovic, I., Skavic, J., & Strinovic, D. (1988). Acetylcholinesterase in the human frontal associative cortex during the period of cognitive development: Early laminar shifts and late innervation of pyramidal neurons. *Neuroscience Letters*, *90*, 107–112.
- Le, T. L., & Hu, X. (1996). Retrospective estimation and correction of physiological artifacts in fMRI by direct extraction of physiological activity from MR data. *Magnetic Resonance in Medicine*, *35*, 290–298.
- Luciana, M., & Nelson, C. A. (1998). The functional emergence of prefrontally-guided memory systems in four- to eight-year-old children. *Neuropsychologia*, *36*, 272–293.
- McCarthy, G., Blamire, A. M., Puce, A., Nobre, A. C., Bloch, G., Hyder, F., Goldman-Rakic, P., & Shulman, R. G. (1994). Functional magnetic resonance imaging of human prefrontal cortex activation during a spatial working memory task. *Proceedings of the National Academy of Sciences, USA*, *91*, 8690–8694.
- Mesulam, M. M., & Geula, C. (1988). Acetylcholinesterase-rich pyramidal neurons in the human neocortex and hippocampus: Absence at birth, development during the life span, and dissolution in Alzheimer's disease. *Annals of Neurology*, *24*, 765–773.
- Miles, C., Morgan, M. J., Milne, A. B., & Moris, E. D. M. (1996).

- Developmental and individual differences in visual memory span. *Current Psychology: Developmental, Learning, Personality, Social*, 15, 53-67.
- Nelson, C. A. (1995). The ontogeny of human memory: A cognitive neuroscience perspective. *Developmental Psychology*, 31, 723-738.
- Ornstein, P. A., Naus, M. J., & Liberty, C. (1975). Rehearsal and organizational processes in children's memory. *Child Development*, 46, 818-830.
- Owen, A., Evans, A. C., & Petrides, M. (1996). Evidence for a two-stage model of spatial working memory processing within the lateral frontal cortex: A positron emission tomography study. *Cerebral Cortex*, 6, 31-38.
- Schwartz, M. L., & Goldman-Rakic, P. S. (1984). Callosal and intrahemispheric connectivity of the prefrontal association cortex in rhesus monkey: Relation between intraparietal and principal sulcal cortex. *Journal of Comparative Neurology*, 226, 403-420.
- Smith, E. E., Jonides, J., & Koeppel, R. A. (1996). Dissociating verbal and spatial working memory using PET. *Cerebral Cortex*, 6, 11-20.
- Strupp, J. P. (1997). STIMULATE: A GUI-based fMRI analysis software package. *Neuroimage*, 3, s607.
- Talairach, J., & Tournoux, P. (1988). *Co-planar stereotaxic atlas of the human brain*. New York: Thieme.
- Thatcher, R. W. (1992). Cyclic cortical reorganization during early childhood. *Brain and Cognition*, 20, 24-50.
- Ungerleider, L. G., Courtney, S. M., & Haxby, J. V. (1998). A neural system for human visual working memory. *Proceedings of the National Academy of Sciences, USA*, 95, 883-890.
- Ungerleider, L. G., & Haxby, J. V. (1994). "What" and "where" in the human brain. *Current Opinion in Neurobiology*, 4, 157-165.
- Wilson, F. A. W., Scalaidhe, S. P. O., & Goldman-Rakic, P. S. (1993, June 25). Dissociation of object and spatial processing domains in primate prefrontal cortex. *Science*, 260, 1955-1958.
- Yakovlev, P. I., & LeCours, A.-R. (1967). The myelogenetic cycles of regional maturation of the brain. In A. Minkowski (Ed.), *Regional development of the brain in early life* (pp. 3-70). Oxford, England: Blackwell Scientific.

Received March 23, 1999

Revision received July 30, 1999

Accepted August 5, 1999 ■